

CASE REPORT

Liver Damage After Breast Plastic Surgery – Clinical Case Report

Ieva Tolmane*,**, Baiba Rozentāle*,***, Jāzeps Keišs*, Viesturs Putniņš****

* State Agency "Infectology center of Latvia"

** Riga Stradins University, Doctoral Studies

*** Riga Stradins University, Infectology and Dermatology Department

**** Laboratory "AHL"

Summary

Since silicone implants were introduced in the early 1960s, those have been widely used for cosmetic and reconstructive breast surgery. Although a recent review has shown no relationship between the silicone breast implant and systemic complications, leakage of the silicone into the tissues and migration to the regional lymph nodes remains a clinical problem. This was the first case in our practice when possibly breast implant material was found in the liver tissue.

Key words: Liver, breast implants, complications.

AIM OF THE DEMONSTRATION

To demonstrate relatively rare complication after breast plastic surgery.

CASE REPORT

38 years old woman presents with discomfort in the upper right quadrant and epigastric region. Complaints last for approximately 5 years, periodically. The patient reports no itching, bleeding, jaundice, nausea or other dyspeptic complaint. Laboratory tests within normal ranges, except mild anemia.

16 years ago patient had plastic operation for breast enlargement. The mammary prosthesis consisted of polyurethane cover and filled with synthetic thermostable rubber of low molecular structure. There were episodes of allergic reactions with face edema, Quincke's edema and lymphadenopathy starting about 9 years ago. Lymph node biopsy: infiltration of macrophages and atrophy of lymph node. Breast implants were removed 8 years ago. After that there was an episode of hepatosplenomegaly and enlarged lymph nodes 5 years ago.

Ultrasound examination: Right lobe of liver slightly enlarged with multiple hypoechoic focuses 3-5mm diameter, Fig.1.

It was decided to perform liver biopsy.

Liver biopsy: accumulation of unknown material (fat, air, lipophile radiopaque) in the portal tracts without significant damage of liver parenchyma. Spear-shaped cholesterol or fatty acid crystals are not found, there is no damage of hepatocytes or Kupffer cells. There are no data of inflammatory or neoplastic process, fig. 2., 3. Conclusion: It is possible that material of breast implant has been spread into organism tissues including lymph nodes and liver.

DISCUSSION

According to literature data there are data of breast implants material spread into lymphatic system and other tissues.

Hydrophilic polyacrylamide gel is a nonresorbable soft tissue filler that has been used as implant material for breast augmentation in some countries, particularly from the Asian continent. Many complications associated with hydrogel use have been reported in the clinical literature including inflammation, persistent mastodynia, formation of multiple lumps, poor cosmetic results, glandular atrophy, and significant spread of hydrogel into the surrounding tissue. Data on long-term toxicity is currently unavailable [1]. Since the silicone implant was introduced in the early 1960s, it has been widely used for cosmetic and reconstructive breast surgery. Although a recent review has shown no relationship between the silicone breast implant and systemic complications, leakage of the silicone into the tissues and migration to the regional lymph nodes remains a clinical problem [2]. Through magnetic resonance spectroscopy and atomic emission spectroscopy, silicon compounds were found in the blood of some women with silicone breast implants; silicone and silica have also been found in liver [3].

Infectology Center of Latvia is specialized into liver diseases differential diagnosis and management. We perform almost one thousand liver biopsies each year, mainly due to chronic viral hepatitis C, but also to diagnose other hepatic diseases, like primary biliary cirrhosis, steatohepatitis, focal liver lesion differentiation and other. This was the first case when possibly breast implant material was found in liver tissue. This case demonstrates very rare and relatively late complication of breast plastic surgery. There is still an open question – what will be the next step? How this material will affect liver tissue in a long term perspective, taking into account that there is a foreign body for many years in the liver and other tissues?

Conflict of interest: None

REFERENCES:

1. Khedher NB, David J, Trop I, Drouin S, Peloquin L, Lalonde L. Imaging findings of breast augmentation with injected hydrophilic polyacrylamide gel: Patient reports and literature review. *Eur J Radiol*, 2011; Apr; 78(1): 104-11
2. Shaaban H, Jmor S, Alvi R. Leakage and silicone lymphadenopathy with cohesive breast implant. *British Journal of Plastic Surgery*, 2003 Vol 56 (5):518-519
3. Yoshida SH, Swan S, Teuber SS, Gershwin ME. Silicone breast implants: Immunotoxic and epidemiologic issues. *Life Sciences*, 1995 Vol 56 (16):1299-1310

Address:

Ieva Tolmane
Linezera street 3, Riga, LV-1006
ieva.tolmane@inbox.lv

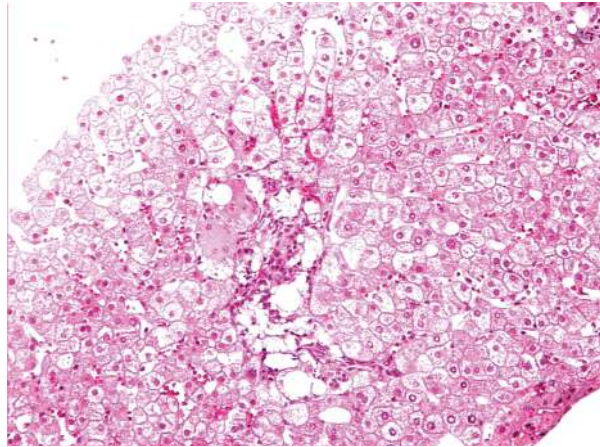


Fig. 2. Liver core biopsy: magnification 100 x (H & E). Dilatation of portal tracts due to foam cells. Foam cells are filled with an empty vacuolas. Morphological structure of hepatocytes is not damaged.

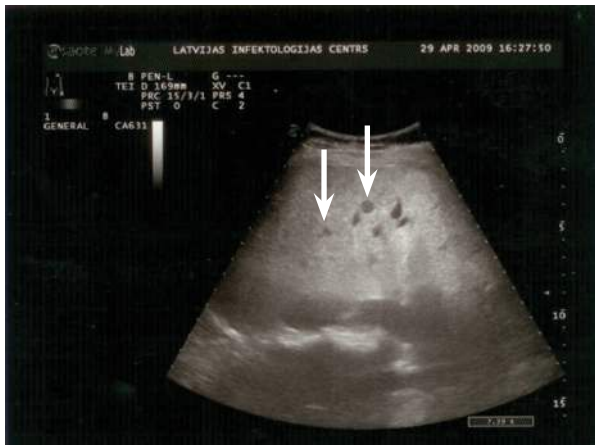

Fig. 1. Right lobe of the liver with hypoechogenic foci, ultrasound.

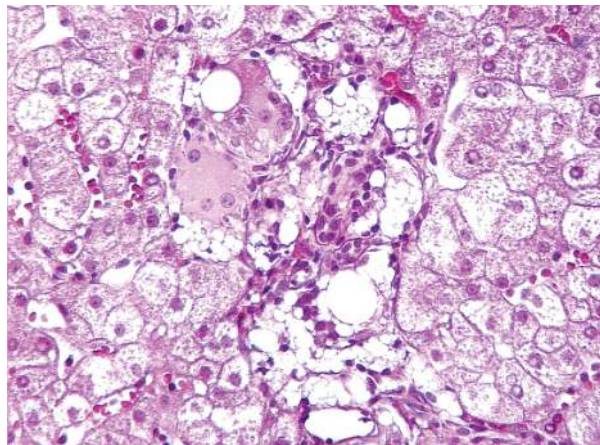


Fig. 3. Liver core biopsy: magnification 400 x (H & E).